

# Endovascular Treatment of Wide-Neck Anterior Circulation Aneurysms: Techniques and Outcomes in 11 Patients

Walid K. Abouzeid MD<sup>1</sup>, Tamer Hasan MD<sup>2</sup>

1. Neurosurgery Department, Faculty of Medicine, Sohag University, Sohag, Egypt

2. Neurosurgery Department, Faculty of Medicine, Alexandria University, Alexandria, Egypt

## Abstract:

### Introduction:

Wide-neck intracranial aneurysms were originally thought to be either untreatable or very difficult to be treated by endovascular method because of the risk of coil protrusion in to the parent vessel. The introduction of the balloon remodeling technique (BRT) and the special stents designed for intracranial use allowed these lesions to be treated by endovascular means. BRT and stent-assisted coiling technique (SACT) were first planned to treat sidewall aneurysms but, with accumulated skill, technical development, Bifurcation and complex-shaped wide-necked aneurysms have been able to be treated by coiling enhanced by BRT and SACT. In this article, we will discuss the inherent welfare and durability of BRT as well as SACT and surgical outcome.

### Objective:

The purpose of this study was to evaluate the safety of the techniques and to address the clinical and radiological outcome of wide-neck anterior circulation aneurysms treated endovascularly via using BRT, or SACT.

### Methods:

Eleven saccular aneurysms, on different location in anterior circle of Willis were treated with standard Guglielmi detachable coils (GDC) coils by using different techniques. All aneurysms were characterized by either wide necks or were small with disapproving neck/ fundus ratio. Patients were followed up both clinically and angiographically for 1 year.

### Results:

Nine Patients (81.8%) treated by using a microcatheter-mounted non detachable balloon to provide a temporary barrier across the aneurysmal neck, and two Patients (17.2%) treated by stent assisted coiling. we were able to deploy GDCs safely within a variety of aneurysms. Among all patients treated, aneurysmal occlusion on follow-up angiography during one year was found in nearly all the patient. Observed or suspected thromboembolic events never occurred in our patients, also we couldn't identify serious complication

### Conclusion:

Although BRT, or SACT of cerebral aneurysms requires manipulation of a second microcatheter and there usages increasing its technical complexity, we believe that the utility of those approaches in treating broad-necked aneurysms encouraging optimal embolization otherwise suboptimally managed by conventional GDC deployment.

### Keywords:

Anterior circulation, Wide neck, Aneurysms, Balloon remodeling, Stent assisted

## Introduction

Endovascular treatment of wide neck intracranial aneurysms is associated with lower morbidity and mortality rates compared with traditional invasive microsurgical clipping which considered durable procedure and well established worldwide in management of those types of aneurysms (1).

Wide-neck considered when the neck is  $\geq 4$  mm, or when Wide-neck ratio is less than the dome/neck 1.5–2 %. Wide neck or even complex intracranial aneurysms were originally thought to be challenging to be treated endovascularly because of the danger of coil protrusion into the main vessel. The introduction of the balloon remodeling technique BRT and later intracranial stents has progressively made these lesions amenable to be endovascularly treated. However, the introduction of additional devices into small intracranial vessels is not only technically demanding, but also may increase the risk of vascular injury and thromboembolism (2-4).

Although balloon-assisted and stent-assisted coiling may be therapeutic options (3-5) in those types of wide neck aneurysms, but also, some technical difficulties, low rates of initial angiographic occlusion and high rates of recurrence are reported in such situations (5-7).

In this report, we present our local experiences with eleven cases with wide-necked anterior circulation intracranial aneurysms.

## Patients and Methods

A retrospective study of wide neck anterior circulation aneurysms seen at Neurosurgery Department, Sohag University hospital from January 2012 to October 2014.

Only 11 patient harboring wide neck anterior circulation aneurysms were primarily selected for endovascular approach who fulfilled the following criteria:

### ❖ Inclusion criteria:

- 1- Small to medium sized aneurysms less than 15mm in size, had a neck size of more than 4 mm or a neck/fundus ratio  $< 1.5-2$ , whatever ruptured or not.
- 2- Not highly tortuous parent artery, or no any vessels or perforators arise from the neck of the aneurysm.
- 3- Absence of intracerebral hemorrhage  $> 35$ ml in volume or subdural hematomas need decompression.
- 4- Presences of severe vasospasm on the initial DSA with medical comorbidities.
- 5- Presence of financial support
- 6- Finally according to patient's desire.

### ❖ All patients subjected to

#### A. Patient data

Including demographic, clinical and radiologic data (Patient age, gender and co-morbidity, rupture state of the aneurysm or not).

SAH evaluated by Hunt & Huss (H&H) grading shown in (table 1)

#### B. Procedure data

Including type of intervention, procedure complication (Thromboembolic events, aneurysm rupture, artery perforation and access site complications).

#### C. Outcome data

##### \* Angiographic outcome

Immediate occlusion grade of the aneurysm was evaluated by Digital subtraction angiography (DSA) at the end of endovascular procedures.

Then aneurysm occlusion grade was re-evaluated at 3 and 6 months follow-ups. Angiographic occlusion was assessed using the 3-point

Raymond classification scale: complete obliteration (Grade A) which equal 100%, residual neck (Grade B) which equal 95-99% and residual aneurysm (Grade C) which equal <95%.

Aneurysmal Recurrence was considered when there was any increase in the size of neck remnant of partially occluded aneurysm or appearance of new neck remnant in previously completely occluded aneurysm in the 1<sup>st</sup> final postoperative DSA.

**\* Clinical outcome**

The patient's outcome was recorded according to Glasgow Outcome Scale (GOS) at discharge (table 2), after 1 and 6 months and at the last follow-up point (mean 8.7 months). Poor outcome was assigned for patient who had GOS of 3 to 5.

❖ **Endovascular approaches:**

**A. Balloon remodeling technique:**

The BRT consists in the temporary inflation of a non-separable balloon across the aneurysm neck during each coil settlement to avoid unintentional coil protrusion into the main artery as initially described by Moret et al(8).

All procedures were conducted with the patient under general anesthesia. Selective micro-catheterization was performed via one of two approaches. First approach, the selected modality and GDC micro catheters were introduced through the same 8F guide system, using single-groin access. In the second approach, bilateral groin pin holes were performed, using two leader catheters for introduction of each microcatheter separately: a 6F sheath/guide catheter for either to the balloon or the stent, and a 5F sheath/guide catheter for the GDC microcatheter. Depending on the requirements of each case, and the selected approach in management. At the end of the procedure, the balloon was removed with no device left in its place in the main vessel.

For the side wall aneurysms compliant remodeling balloon microcatheters are the Hyper Glide™ (compatible with 0.01000 Transend EX micro guide wire), and more compliant Hyper form balloon microcatheter (compatible with 0.00 micro guide wire) for the bifurcating aneurysms.

**B. Stent-assisted coiling:**

wide-neck aneurysms were still non-addressed by both reconstructive surgical and endovascular techniques until the appearance of dedicated intracranial self-expandable stent. Stent placement across the aneurysmal neck, with following coil packing of the aneurysm, has been more and more widely adopted with time, especially for complex wide-necked aneurysms, so as to steady the coil mass inside the aneurysmal sac and also to avoid herniation of the coil into the main parent artery.

The SACT usage had some substantial considerations, such as the need to use antiplatelet therapy with the accompanying non avoidable dangers of intracranial bleeding.

There are two major different types, close type (e.g., Enterprise™); and open-cell type (e.g., Neuroform™), designs for the construction of self-expanding stents dedicated to the intracranial use. We preferred Open-cell design as stents better cover the aneurysm neck when compared to close-cell stents, and induce less straightening of the vessel. However, open-cell stents may show increased opening of cells and outward prolapse of struts into an aneurysm neck when situated at the convexity of the curvature, whereas at the concavity, struts, or stent segments may protrude inward.

Two procedures may be proposed. Firstly, the coil delivery micro- catheter can be placed first inside the aneurysmal lumen in order to allow coil delivery and then the stent is located and immediately delivered across the aneurysmal neck (what is called the "jailed-catheter technique") which was used in our study

Secondly, the stent may be first put across the aneurysmal neck and then the coiling microcatheter is placed within the sac through the stent struts (trans-cell technique) which never addressed in our limited cases.

#### ❖ Statistical Analysis:

Data were analyzed using Microsoft Excel 2013 software and IBM-SPSS version 22, quantitative data were expressed as mean  $\pm$  SD; while qualitative data were expressed as number and percentage. Pearson Chi Square statistic was used to compare percentages of qualitative data. P value less than  $<0.05$  was considered significant

#### Results:

Individual data of our study group was listed in (table 3)

In our study male 7 patients (63.6%) more affected than females. The age ranged from 36 to 71 years mean age 57.7 years old. Wide neck aneurysms were more common on the right side (n = 6) than left side (n= 2). The remaining 3 cases had anterior communicating artery (ACOM) aneurysms (n= 3) (table 4).

Size of aneurysms range from (4 –15mm), and size of neck range from (4-5.5mm)(table 5).

Guided by inclusion parameters, in addition to parent artery size, aneurysmal configuration, clinical state of the patient (ruptured or not), and neuroendovascular surgeon experience were collectively advocated to select the expected ideal approach for each patient.

According to previously mentioned parameters, we recommended the SACT in parent artery vessel more than 3mm, in size, non-ruptured, non-bifurcating aneurysms, neck is wider than expected and surgeon" decision toward prevents coil migration in the parent artery after the procedure, or recurrence, enables dense packing in aneurysms, and induces significant intra-aneurysmal flow modification, in addition to surgeon experience in stent delivery. Otherwise BAT was recommended.

Out of 11 patients, nine patients (81.8%) needed balloon-assisted remodeling of the aneurysmal base for treatment with GDC and 2 patients (18.2%) treated by stent assisted coiling approach (figure 1). As regards the aneurysmal location, it was clear that MCA bifurcation aneurysm (MCAB), ACOM, and M1 aneurysms (27.2%) was equally distributed, and only 2 patients (18.4) located at the course of internal carotid artery (ICA).

Subarachnoid hemorrhage(SAH) was presented in 7 patients (63.6%) as a clinical manifestation, (H&H grade I in 2 patients, grade II in 3 cases, and grade III in 2 patients)with accidentally discovered in 2 cases, and severe headache in 2 patients (figure 2).

In our study, complete primary occlusion (100%) was achieved in 4 patients (36.6%), which increased to six cases during follow up period (54.5%). Nearly total occlusion (95-99%) was achieved in our patients by 63.6%, and 27.2% at 1ry occlusion, and follow up respectively. One patient only (9%) revealed subtotal occlusion with aneurysmal remnant ( $<95\%$ ) after 6 months follow up, which need no more surgical intervention during follow up and the patient was clinically good.

One patient only lost during follow up.

According to GOS we obtained GR scale in 7 patients (63.6%) after 30days from 1ry intervention, and increased to 72.7 % after 6 months follow up, and MD in 4 patients (36.3%) which decreased to 9% during follow up, and recorded one patient only with SD at follow up.

The selected treatment modality whether balloon, or stent, techniques was feasible in all cases of our study.

No observed critical complication in selected approach such as thromboembolic, hemorrhagic complications, more than groin hematoma in 1 patient which resolved spontaneously.

## Discussion

Wide-necked intracranial aneurysms represent one of the most unfavorable aneurysm configurations. Various devices and techniques have been introduced to overcome the technical limitations associated with treating wide-necked intracranial aneurysms, including three-dimensional coils (9), multiple microcatheter (10-12), balloon remodeling technique (8), intracranial stents(13), flow diverter devices (14) and neck-bridge device (15).

We targeted to identify the feasibility, safety, and efficacy of using balloon, and stent for the treatment of wide-necked anterior circulation aneurysms.

Several authors (7, 16-19) have been reported the classic "BRT", using a single low-compliance balloon, was initially limited to sidewall aneurysms, and was often inadequate for protection of both the neck and arterial branches of complex bifurcation aneurysms, but Nowadays, different types of balloon are available I the market with different indication also.

In our study, the HyperGlide™ (compatible with 0.01000 micro guide wire), was recommended in side branching aneurysms, giving to the operator the opportunity to navigate coils while the balloon is still inflated, and the navigation of the balloon through the circle of Willis to cross and protect the aneurysm neck (e.g., to navigate from the internal carotid, ACOM, and M1 aneurysms).

For bifurcated lesions, the use of more compliant balloon such as HyperForm™ (compatible with 000 micro guide wire), and the technique consists in the navigation of a dual-lumen balloon in front of the neck to allow coil deposition through the second lumen of the balloon microcatheter. (e.g. to navigate in MCA bifurcating aneurysms).

We agree the definition of the compliance by the propensity of the balloon to change its cylindrical shape to the anatomy of the vessel in which it is inflated, allows the treatment of complex wide-necked bifurcation aneurysms for which the standard emboilization method would not have allowed safe (regarding the patency of bifurcation arterial branches) endovascular occlusion (9, 11, 14).

The use of BRT has raised some concerns about potential added morbidity over the standard coiling procedure, and the two most frequent and feared complications of the endovascular treatment of intracranial aneurysms are thromboembolic events and aneurysm perforation.

The CLARITY study which revealed that either conventional coil emboilization or BRT showed that both techniques had similar safety in terms of perioperative complications and clinical outcome (20-24). The overall rate of treatment-related complications, with or without clinical manifestations, was 17.4% with coil emboilization and 16.9% with BRT.

Shapiro et al. (25), confirmed the safety of BRT in both ruptured and unruptured aneurysms as they recorded serious event or death in 2.7% in the stand-alone coiling group compared to 1.7% in the BRT group who had ruptured aneurysms. Also, the results of unruptured aneurysms in their study revealed symptomatic event or death in 0.6% in the stand-alone group and 0.9% in the BRT group. they stated also that the rate of intraoperative rupture was around 3.4% in the standard coiling group, 1.7% in the remodeling technique group among those with ruptured aneurysms. In the cases with unruptured aneurysms, the rate of intraoperative ruptures was 1.4% in standard coiling technique and 1.8% in the remodeling technique groups.

In our study we could address obviously the same conclusion of the previous reports of the safety and efficacy of BRT in treatment of wide neck aneurysms whatever ruptured or not with no dangerous complication, and good clinical, and angiographic outcome.

According to our knowledge the introduction of self-expandable intracranial stent, and stent placement across the aneurysmal neck, followed by coil packing of the aneurysm, has increasingly been more widely accepted, chiefly for wide-necked complex aneurysms, so as to stabilize the coil mass inside the aneurysmal sac and to avoid herniation of the coil into the main or parent artery, which broadly accepted by others (26-28).

With increased practice and experience, SACT has been used to treat a larger range of aneurysms, other than the wide-necked, or complex aneurysms; with the impression of the possibility of reduced risk of recurrence of the aneurysms (2, 27, 28).

However, the necessity of antiplatelet therapy carries high risks of intracranial bleeding, and, moreover, the antiplatelet therapy is limited in the setting of subarachnoid hemorrhage for the majority of the operators (29-31). So we preferred to avoid SACT in SAH and that explain the very small number of cases that treated via SACT in our study.

In a review article, Shapiro et al. (28) reported an overall complication incidence of 19%, and a death incidence of around 2%. Thromboembolic complications were most prevalent with a rate of nearly 10%, caused death in 0.6% of treated cases. Hemorrhagic complications occurred in 2.2% of cases but was highly linked with mortality, causing a mortality rate of 0.9% of the total patients.

A relatively more recent study done by Nishido et al. (32) reported ischemic complication rates of around 7% and hemorrhagic complications of 2.3% with an overall mortality rate of 2.7% with SACT.

Geyik et al. (33) in a study done on 500 SACT aneurysms, stated that the complication rate were 5.6% for the thromboembolic and 0.8% for the hemorrhagic complications, with a mortality rate of 0.8%.

In our study although the very small limited number of cases can't judge the real percentage of any thromboembolic, hemorrhagic, or even recurrence of aneurysm, but also we didn't catch any of the previously reported complication, in addition good clinical and angiographic outcomes.

We need to increase the number of the patients, modalities of approach, and to prolong the time of angiographic follow up to encounter the ideal plane for those types of aneurysms.

## **Conclusion**

Both balloon-remodeling technique, and stent assisted coiling are versatile reconstructive and safely effective options in the treatment of wide neck aneurysms than stand-alone coiling.

Although BRT and SACT improve the filling of wide neck aneurysms, and decrease the rate of the recurrence, but also remains more hazardous than stand-alone coiling in keeping with augmented risks of both ischemic and hemorrhagic insults, which not addressed in our study.

Wise case selection should be attempted.

## References:

1. Guglielmi G, Vinuela F, Briganti F, Duckwiler G, Carotid-cavernous fistula caused by a ruptured intracavernous aneurysm: endovascular treatment by electrothrombosis with detachable coils, *Neurosurgery*, **31(3)**, 591-6; discussion 6-7, 1992
2. Pötin M, Blanc R, Balloons and stents in the endovascular treatment of cerebral aneurysms: vascular anatomy remodeled, *Frontiers in neurology*, **5**, 2014
3. Akiba Y, Murayama Y, Vinuela F, Lefkowitz MA, Duckwiler GR, Gobin YP, Balloon-assisted Guglielmi detachable coiling of wide-necked aneurysms: Part I--experimental evaluation, *Neurosurgery*, **45(3)**, 519-27; discussion 27-30, 1999
4. Aletich VA, Debrun GM, Misra M, Charbel F, Ausman JI, The remodeling technique of balloon-assisted Guglielmi detachable coil placement in wide-necked aneurysms: experience at the University of Illinois at Chicago, *Journal of neurosurgery*, **93(3)**, 388-96, 2000
5. Nelson PK, Levy DI, Balloon-assisted coil embolization of wide-necked aneurysms of the internal carotid artery: medium-term angiographic and clinical follow-up in 22 patients, *AJNR American journal of neuroradiology*, **22(1)**, 19-26, 2001
6. Cottier JP, Pasco A, Gallas S, Gabrillargues J, Cognard C, Drouineau J, et al., Utility of balloon-assisted Guglielmi detachable coiling in the treatment of 49 cerebral aneurysms: a retrospective, multicenter study, *AJNR American journal of neuroradiology*, **22(2)**, 345-51, 2001
7. Baldi S, Mounayer C, Pötin M, Spelle L, Moret J, Balloon-assisted coil placement in wide-neck bifurcation aneurysms by use of a new, compliant balloon microcatheter, *AJNR American journal of neuroradiology*, **24(6)**, 1222-5, 2003
8. Moret J, Cognard C, Weill A, Castaings L, Rey A, The "Remodelling Technique" in the Treatment of Wide Neck Intracranial Aneurysms. Angiographic Results and Clinical Follow-up in 56 Cases, *Interventional neuroradiology : journal of peritherapeutic neuroradiology, surgical procedures and related neurosciences*, **3(1)**, 21-35, 1997
9. Cloft HJ, Joseph GJ, Tong FC, Goldstein JH, Dion JE, Use of three-dimensional Guglielmi detachable coils in the treatment of wide-necked cerebral aneurysms, *AJNR American journal of neuroradiology*, **21(7)**, 1312-4, 2000
10. Kwon BJ, Seo DH, Ha YS, Lee KC, Endovascular Treatment of Wide-necked Cerebral Aneurysms with an Acute Angle Branch Incorporated into the Sac: Novel methods of Branch Access in 8 Aneurysms, *Neurointervention*, **7(2)**, 93-101, 2012
11. Kwon OK, Kim SH, Oh CW, Han MH, Kang HS, Kwon BJ, et al., Embolization of wide-necked aneurysms with using three or more microcatheters, *Acta neurochirurgica*, **148(11)**, 1139-45; discussion 45, 2006
12. Kwon OK, Kim SH, Kwon BJ, Kang HS, Kim JH, Oh CW, et al., Endovascular treatment of wide-necked aneurysms by using two microcatheters: techniques and outcomes in 25 patients, *AJNR American journal of neuroradiology*, **26(4)**, 894-900, 2005
13. De Paula Lucas C, Pötin M, Spelle L, Moret J, Stent-jack technique in stent-assisted coiling of wide-neck aneurysms, *Neurosurgery*, **62(5 Suppl 2)**, ONS414-6; discussion ONS6-7, 2008
14. Lubicz B, Collignon L, Raphaeli G, Pruvo JP, Bruneau M, De Witte O, et al., Flow-diverter stent for the endovascular treatment of intracranial aneurysms: a prospective study in 29 patients with 34 aneurysms, *Stroke*, **41(10)**, 2247-53, 2010
15. De Keukeleire K, Vanlangenhove P, Defreyne L, Evaluation of a neck-bridge device to assist endovascular treatment of wide-neck aneurysms of the anterior circulation, *AJNR American journal of neuroradiology*, **29(1)**, 73-8, 2008

- 16.Spiotta AM, Miranpuri A, Chaudry MI, Turner RDt, Turk AS, Combined balloon stent technique with the Scepter C balloon and low-profile visualized intraluminal stent for the treatment of intracranial aneurysms, *Journal of neurointerventional surgery*, **5 Suppl 3**iii79-iii82, 2013
- 17.Spiotta AM, Miranpuri A, Hawk H, Chaudry MI, Turk AS, Turner RD, Balloon remodeling for aneurysm coil embolization with the coaxial lumen Scepter C balloon catheter: initial experience at a high volume center, *Journal of neurointerventional surgery*, **5(6)**, 582-5, 2013
- 18.Clarencon F, Perot G, Biondi A, Di Maria F, Szatmary Z, Chiras J, et al., Use of the Ascent balloon for a 2-in-1 remodeling technique: feasibility and initial experience: case report, *Neurosurgery*, **70(1 Suppl Operative)**, 170-3; discussion 3, 2012
- 19.Arat A, Cil B, Double-balloon remodeling of wide-necked aneurysms distal to the circle of Willis, *AJNR American journal of neuroradiology*, **26(7)**, 1768-71, 2005
- 20.Pierot L, Cognard C, Anxionnat R, Ricolfi F, Investigators C, Endovascular treatment of ruptured intracranial aneurysms: factors affecting midterm quality anatomic results: analysis in a prospective, multicenter series of patients (CLARITY), *AJNR American journal of neuroradiology*, **33(8)**, 1475-80, 2012
- 21.Pierot L, Cognard C, Ricolfi F, Anxionnat R, investigators C, Mid-term anatomic results after endovascular treatment of ruptured intracranial aneurysms with Guglielmi detachable coils and Matrix coils: analysis of the CLARITY series, *AJNR American journal of neuroradiology*, **33(3)**, 469-73, 2012
- 22.Cognard C, Pierot L, Anxionnat R, Ricolfi F, Clarity Study G, Results of embolization used as the first treatment choice in a consecutive nonselected population of ruptured aneurysms: clinical results of the Clarity GDC study, *Neurosurgery*, **69(4)**, 837-41; discussion 42, 2011
- 23.Pierot L, Cognard C, Anxionnat R, Ricolfi F, Investigators C, Ruptured intracranial aneurysms: factors affecting the rate and outcome of endovascular treatment complications in a series of 782 patients (CLARITY study), *Radiology*, **256(3)**, 916-23, 2010
- 24.Pierot L, Cognard C, Ricolfi F, Anxionnat R, Investigators C, Immediate anatomic results after the endovascular treatment of ruptured intracranial aneurysms: analysis in the CLARITY series, *AJNR American journal of neuroradiology*, **31(5)**, 907-11, 2010
- 25.Shapiro M, Babb J, Becske T, Nelson PK, Safety and efficacy of adjunctive balloon remodeling during endovascular treatment of intracranial aneurysms: a literature review, *AJNR American journal of neuroradiology*, **29(9)**, 1777-81, 2008
- 26.Higashida RT, Halbach VV, Dowd CF, Juravsky L, Meagher S, Initial clinical experience with a new self-expanding nitinol stent for the treatment of intracranial cerebral aneurysms: the Cordis Enterprise stent, *AJNR American journal of neuroradiology*, **26(7)**, 1751-6, 2005
- 27.Lawson MF, Newman WC, Chi YY, Mocco JD, Hoh BL, Stent-associated flow remodeling causes further occlusion of incompletely coiled aneurysms, *Neurosurgery*, **69(3)**, 598-603; discussion -4, 2011
- 28.Shapiro M, Becske T, Sahlein D, Babb J, Nelson PK, Stent-supported aneurysm coiling: a literature survey of treatment and follow-up, *AJNR American journal of neuroradiology*, **33(1)**, 159-63, 2012
- 29.Golshani K, Ferrel A, Lessne M, Shah P, Chowdhary A, Choulakian A, et al., Stent-assisted coil emboilization of ruptured intracranial aneurysms: A retrospective multicenter review, *Surgical neurology international*, **384**, 2012
- 30.McDonald JS, Norgan AP, McDonald RJ, Lanzino G, Kallmes DF, Cloft HJ, In-hospital outcomes associated with stent-assisted endovascular treatment of unruptured cerebral aneurysms in the USA, *Journal of neurointerventional surgery*, **5(4)**, 317-20, 2013

31. Bodily KD, Cloft HJ, Lanzino G, Fiorella DJ, White PM, Kallmes DF, Stent-assisted coiling in acutely ruptured intracranial aneurysms: a qualitative, systematic review of the literature, *AJNR American journal of neuroradiology*, **32(7)**, 1232-6, 2011
32. Nishido H, Piotin M, Bartolini B, Pistocchi S, Redjem H, Blanc R, Analysis of complications and recurrences of aneurysm coiling with special emphasis on the stent-assisted technique, *AJNR American journal of neuroradiology*, **35(2)**, 339-44, 2014
33. Geyik S, Yavuz K, Yurttutan N, Saatci I, Cekirge HS, Stent-assisted coiling in endovascular treatment of 500 consecutive cerebral aneurysms with long-term follow-up, *AJNR American journal of neuroradiology*, **34(11)**, 2157-62, 2013

**Table 1. Clinical grading systems for patients after SAH**

Grade	Hunt and Hess
<b>I</b>	Asymptomatic, minimal headache or slight nuchal rigidity
<b>II</b>	Moderate to severe headache, nuchal rigidity, neurological deficit confined to cranial nerve palsy
<b>III</b>	Drowsiness, confusion or mild focal deficit
<b>IV</b>	Stupor, moderate to severe hemiparesis, possibly early decerebrate rigidity, and vegetative disturbances.
<b>V</b>	Deep coma, decerebrate rigidity, moribund appearance

**Table 2. Glasgow Outcome Scale (GOS)**

GOS Grade	Neurological status
<b>1</b>	Good recovery: patient can lead a full and independent life with or without minimal neurological deficit
<b>2</b>	Moderately disabled: patient has neurological or intellectual impairment but is independent
<b>3</b>	Severely disabled: patient is conscious but totally dependent on others to get through daily activities
<b>4</b>	Vegetative state: patient is breathing spontaneously but remains unresponsive
<b>5</b>	Dead

**Table 3. Individual data in 11 patients with different wide neck aneurysms treated by coiling with different-assisted approach**

Case No	Age (y)/Sex	Presenting Finding	Location	Size (mm)/Aneurysm neck mm	Approach	Occlusion Rate after EVT	Occlusion Rate after 6 months	GOS at 30 days	GOS at 6 months
1	69/M	Severe headache, No SAH	Right, MCA bifurcation	10x 5/4.4	Balloon assisted	<b>Grade B</b>	<b>Grade A</b>	<b>Grade 1</b>	<b>Grade 1</b>
2	52/M	Accidently discovered	ACOM AN	14x 6/4	Balloon assisted	<b>Grade B</b>	<b>Grade A</b>	<b>Grade 2</b>	<b>Grade 1</b>
3	69/M	Severe headache, No SAH	Left, M1	11x 4 /5.2	Stent	<b>Grade A</b>	<b>Grade A</b>	<b>Grade 1</b>	<b>Grade 1</b>
4	66/F	SAH	Right, MCA bifurcation	4x 3/4	Balloon assisted	<b>Grade B</b>	*	<b>Grade 2</b>	*
5	49/M	SAH	Right M1	10x 6/4.2	Balloon assisted	<b>Grade A</b>	<b>Grade A</b>	<b>Grade 1</b>	<b>Grade 1</b>
6	69/F	SAH	Right, MCA bifurcation	15x 7/4.5	Balloon assisted	<b>Grade B</b>	<b>Grade A</b>	<b>Grade 2</b>	<b>Grade 3</b>
7	59/F	Accidently discovered	Right, M1	13x 4 /5.5	stent	<b>Grade A</b>	<b>Grade B</b>	<b>Grade 1</b>	<b>Grade 1</b>
8	71/M	SAH	ACOM AN	11x 5/4	Balloon assisted	<b>Grade B</b>	<b>Grade A</b>	<b>Grade 1</b>	<b>Grade 1</b>
9	68/F	SAH	ACOM AN	13x 5/4.5	Balloon assisted	<b>Grade B</b>	<b>Grade C</b>	<b>Grade 2</b>	<b>Grade 2</b>
10	43/M	SAH	Left, IC carotid cave AN	12x 4 /4.3	Balloon assisted	<b>Grade B</b>	<b>Grade B</b>	<b>Grade 1</b>	<b>Grade 1</b>
11	53/M	SAH	Right, IC-Ophthalmic AN	9x 4/4	Balloon assisted	<b>Grade A</b>	<b>Grade B</b>	<b>Grade 1</b>	<b>Grade 1</b>

\* Lost in follow up      AN: aneurysm

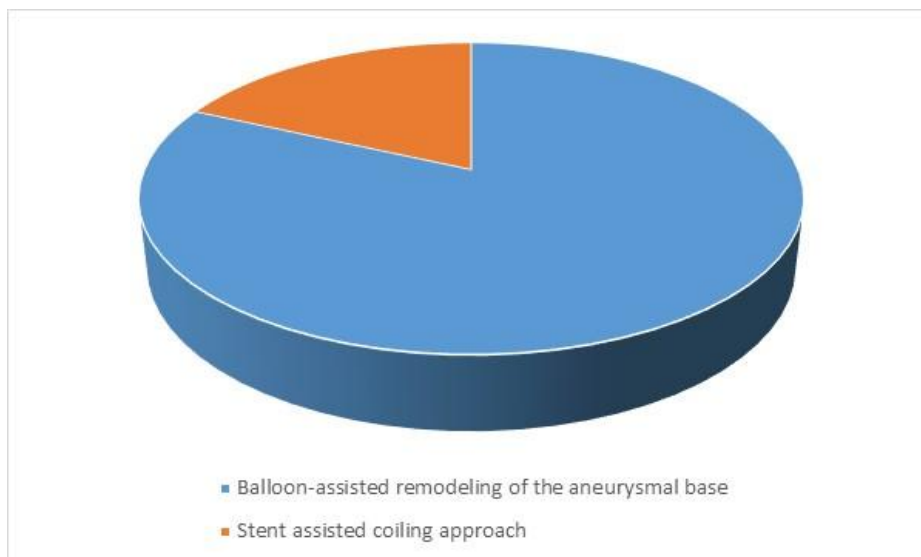
**Table 4. Demographic data of the study group**

	Item	Value
Sex	Male	4(26.4%)
	Female	7(63.6%)
Age	Mean±SD	57.73±11.94
	Median(range)	59(36-71)
Location	Wide neck aneurysm (right)	6(54.5%)
	Wide neck aneurysm (left)	2(27.3%)
	ACOM aneurysm	3(18.2%)

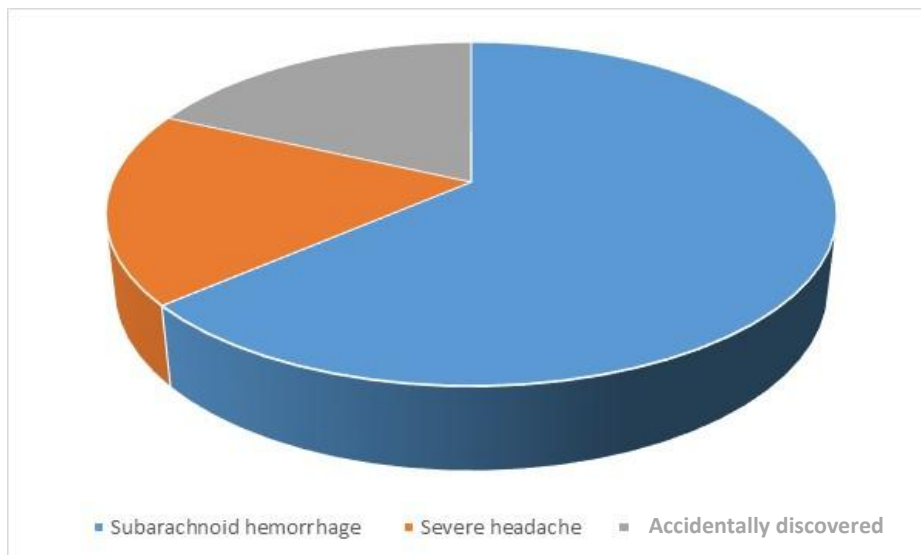
**Table 5. Aneurysm data**

	Item	Value
Aneurysm size	Mean±SD	7.27±1.73
	Median(range)	7.2(4-15)
Neck size	Mean±SD	4.42±0.51
	Median(range)	4.3(4-5.5)

**Figure 1. Treatment of cases**



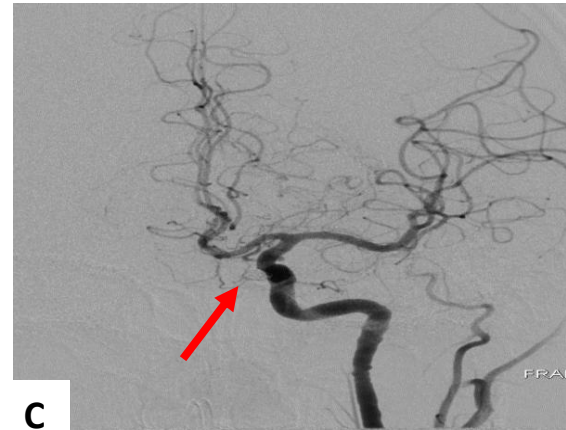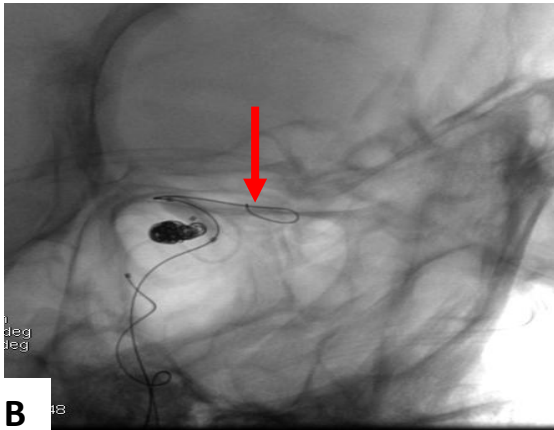
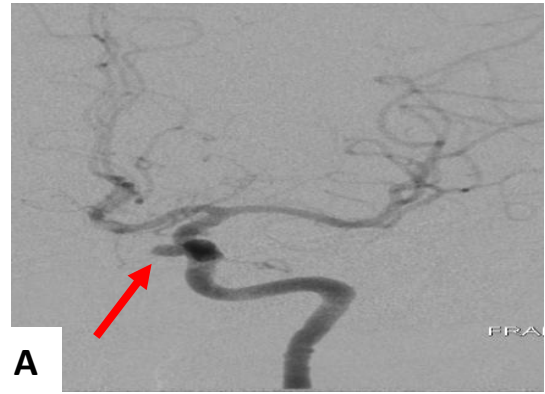
**Figure 2. Clinical presentation of the study group**



### Case presentations:

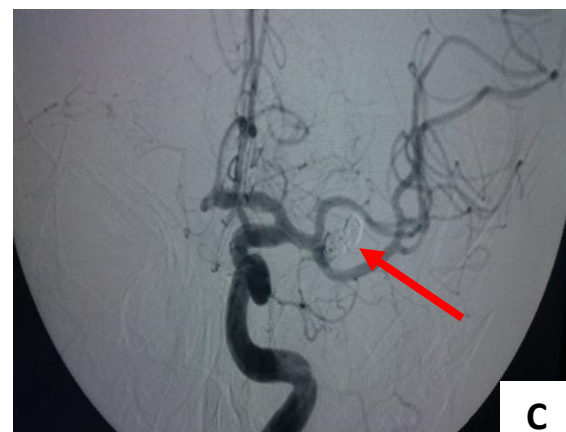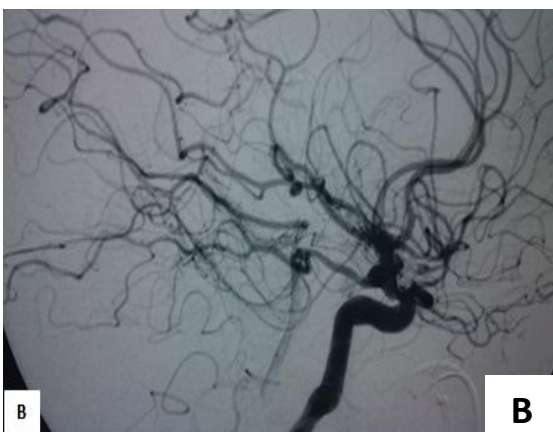
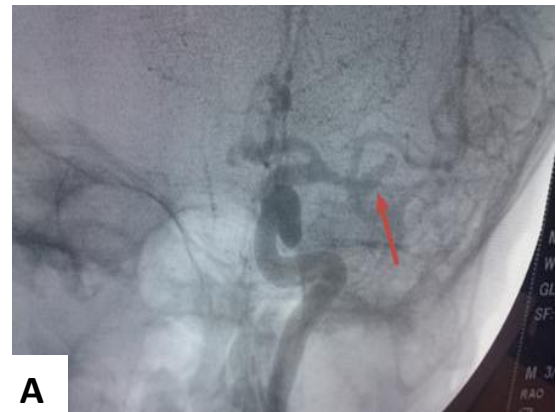#### Case 1:

37 years old female patient presented with headache, Balloon assisted coiling 9x5 mm neck 4 mm, IC-ophthalmic aneurysm.(A) pre-embolization, AP view, showing IC-Ophthalmic aneurysm(red arrow) (B) intraoperative balloon remodeling(red arrow) with coil mass (C) post embolization with nearly total occlusion of the aneurysm (red arrow)



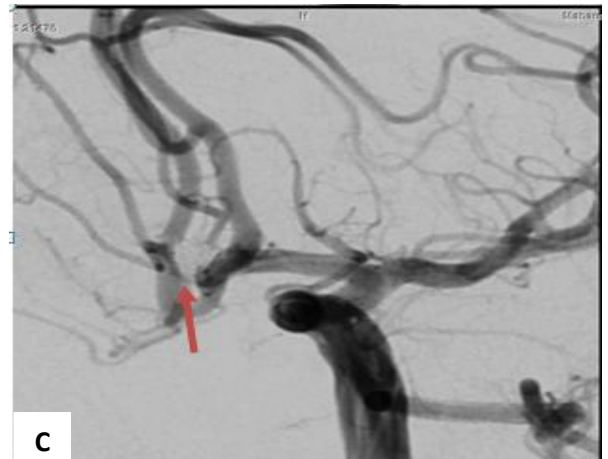
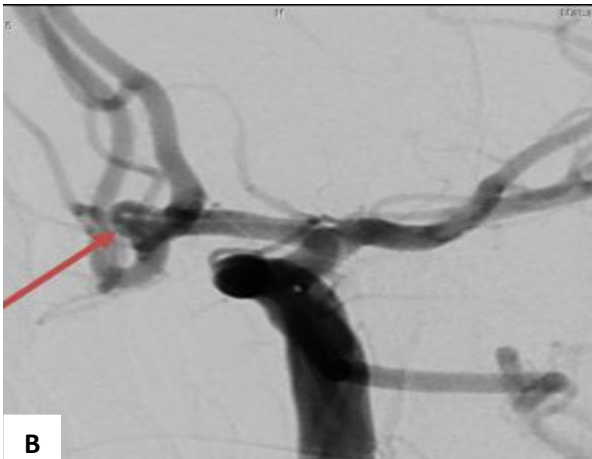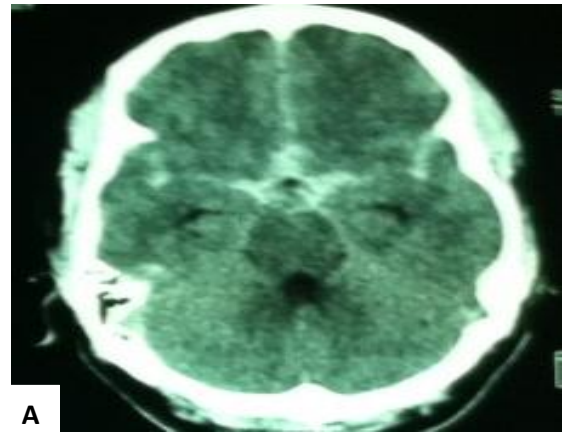
#### Case 2:

50 years old male patient presented with SAH, H&H grade1, stent assisted coiling 11x 4 mm neck 4 mm, MCA bifurcation aneurysm. (A) pre-embolization AP view (B) lateral view (C) post-embolization with stent deployment (red arrow)



### Case 3:

30 years old male patient presented with SAH, H&H grade 1, balloon assisted coiling 4x3mm neck 4 mm ACOM aneurysm. (A) CT with SAH (B) pre-embolization (C) post embolization,



## الملخص العربي

# دور البالونات الدقيقة المؤقتة والدعامات المخية الدقيقة في علاج التمددات الشريانية المخية ذات القاعدة العريضة.

### المقدمة

يعتبر استخدام القسطرة المخية في علاج التمددات الشريانية ذات القاعدة العريضة بواسطة الملفات الحلزونية من أصعب التقنيات وذلك لصعوبة حقن هذه التمددات بصورة كاملة. لذا فنحن نعتقد أن استخدام البالونات الدقيقة المؤقتة والدعامات المخية الدقيقة في علاج التمددات الشريانية يعتبر طريقه آمنة وفعالة في العلاج.

### المرضى والطرق

قمنا باختيار أحد عشر مريضاً يعانون من تمددات شريانية ذات قاعدة عريضة بالدوره المخيه الاماميه في المخ بمساعدة البالونات الدقيقة المؤقتة والدعامات المخية الدقيقة فقد تم حقن هذه التمددات بواسطة الملفات الحلزونية الدقيقة ، وقد تم اخضاع هؤلاء المرضى للمتابعة لمدة عام من تاريخ الحقن.

### النتائج

بعد عام من المتابعة فقد تبين لنا فاعلية استخدام هذه الطريقة في حقن وعلاج هذا النوع من التمددات الشريانية بصورة كاملة.

### الخلاصة

يعتبر استخدام البالونات الدقيقة المؤقتة والدعامات المخية الدقيقة من أكثر الطرق أماناً وأكثرها فاعلية في علاج التمددات الشريانية المخية ذات القاعدة العريضة بواسطة الملفات الحلزونية الدقيقة